

Safety and Efficacy of Using MaiLi® Precise by Mean of Intradermal Injections for Correcting Perioral Fine Lines

Paloma Borregón¹, Juan Caicedo², Raphaëlle Glacet^{3,*}, Erick Santaella⁴, and Franco Vercesi⁵

¹Clínica Kalosia, Madrid, Spain

²Cclinics, Valencia, Spain

³Cremer Consulting, Strasbourg, France

⁴ERSA Medical & Aesthetics, Monterrey, Mexico

⁵Centro Medico Galeno, Milan, Italy

*Corresponding author: Raphaëlle Glacet, Cremer Consulting, 14 rue Sleidan, FR-67000 Strasbourg, France, Tel: +33 (0)3 88 35 14 72; E-mail: gmc@cremerconsulting.com

Received: 14 Dec, 2023 | Accepted: 21 Dec, 2023 | Published: 27 Dec, 2023

Citation: Borregón P, Caicedo J, Glacet R, Santaella E, Vercesi F (2023) Safety and Efficacy of Using MaiLi® Precise by Mean of Intradermal Injections for Correcting Perioral Fine Lines. *J Clin Cosmet Dermatol* 7(2): dx.doi.org/10.16966/2576-2826.178

Copyright: ©2023 Borregón P, et al. This is an open-access article distributed under the terms of the Creative Commons Attribution License, which permits unrestricted use, distribution, and reproduction in any medium, provided the original author and source are credited.

Abstract

Introduction: Over the last twenty years, dermal fillers have become the backbone for rejuvenating the perioral area, which is one of the most difficult areas to treat. Due to the development of highly sophisticated fillers with radically different rheological properties and innovating techniques, it has become possible to correct specific regions with more natural results than before. This four-center pilot study sought to investigate the efficacy and safety of MaiLi® Precise in correcting fine-line wrinkles of the perioral area.

Material and Methods: MaiLi® Precise is a recently introduced Hyaluronic Acid (HA) filler, harnessing the OxiFree™ technology, for suppleness, flexibility, and high longevity. These properties were deemed particularly suitable for correcting fine-line perioral wrinkles. All injections were performed using intradermal injections, with the fluid HA injected in a very superficial manner, resulting in the formation of very small papules at the wrinkle, disappearing within 1-2 hours. Follow-up occurred at one (T1) and three months (T2) post-injection. Treatment effectiveness was evaluated using the Global Aesthetic Improvement Scale (GAIS), as was the satisfaction of the subjects and investigators. Adverse Events (AEs) were also reported.

Results: Overall, 20 patients aged 56 years on average, from four centers, were injected MaiLi® Precise into the perioral area to correct perioral lines using intradermal injections. No specific safety concerns were detected, given that AEs remained mild, were almost all resolved by T1, and were completely absent by T2. Patient and physician satisfaction were both >90% during follow-up. All physicians attributed improved, much improved, or very much improved GAIS scores at T1 and T2, indicating a marked improvement in appearance after injection.

Conclusion: Based on the current study results, MaiLi® Precise was shown to be safe and provided satisfactory results from both the patient and the physician's points of view during a 3-month follow-up.

Keywords: Hyaluronic acid; Perioral area; Skin rejuvenation; OxiFree™ technology; MaiLi® filler, Fine lines; Intradermal injection

Introduction

The perioral region refers to the lower one-third of the face, which comprises the upper and lower lips, the cheek-lip grooves or nasolabial folds, and the chin. Ageing signs at this region are among the key reasons for patients seeking treatment [1]. Indeed, this region undergoes significant changes during ageing that likely contribute to a “displeased” or “sad” expression [2]. These changes include fine wrinkling around the lips, deep nasolabial and mentolabial folds, elongation and flattening of the upper lip, downturned corners of the mouth, marionette lines, as well as chin irregularities. The perioral region is the most concerned area for facial rejuvenation. Different options exist, Hyaluronic Acids (HAs) being commonly

used [3]. Since 1998, revolumization of facial structures using HA dermal fillers has been instrumental in reducing signs of ageing and increasing attractiveness [4-6]. In the following years, many different HA filler brands and formulations were manufactured, with differing viscoelastic properties [7,8]. Lidocaine was added to certain gels to increase patient compliance [9].

This perioral region remains one of the most difficult areas to treat, owing to its highly dynamic nature. Wrinkles within the cutaneous lip areas range from fine, almost imperceptible lines to multiple deep etchings, generally referred to as barcodes. Previous attempts of correcting these areas with fillers showed that subcutaneous ridges or overcorrection may be generated in relation with the rheological properties of previous HA fillers [10].

In consequence of this, an innovative manufacturing technology for producing novel HA fillers was developed, with reference to MaiLi®'s OxiFree™ technology, which was launched by Sinclair. The core strength of this technology lies in the cross-linking of HA under inert atmosphere, which is followed by extracting reactive oxygen species during the manufacturing process. This procedure was initially meant to preserve the intrinsic properties of the high-molecular-weight HA chains. Owing to this new technology, HA fillers with improved rheological properties were generated that exhibit both strong projection capacities and suppleness, along with longevity and their striking ability to volumize facial tissues [11-14]. Another key element for treating wrinkles in the cutaneous lip areas lies in the injection technique. To smooth expression wrinkles around the mouth, also called barcodes, HA application using intradermal injections appears particularly appropriate. When using intradermal injections, a very fluid HA is injected in a very superficial manner [15,16]. Upon this injection technique, the cross-linked HA is quickly absorbed, thereby filling the fine line for several months. This is meant to slow the facial ageing process.

The investigational product for this study was the MaiLi® HA filler, in its variant named MaiLi® Precise, manufactured according to the OxiFree™ technology and launched by Sinclair [12,14]. We sought to report the results from this prospective, multicenter pilot study designed to assess the efficacy and associated safety profile of the MaiLi® Precise HA filler injected into the perioral region by means of intradermal injections.

Material and Methods

Study design and population

This was a prospective multicenter pilot study conducted at four investigational sites located in Spain (n=2), Italy (n=1), and Mexico (n=1), as part of a post-marketing clinical follow-up program. Each center was invited to recruit five patients to be injected (T0) with MaiLi® Precise using intradermal injections, with multiple punctures, evenly spaced 1-3 mm apart, using a superficial 1-2 mm intradermal needle insertion. The volume injected depended on the desired effect. Follow-up visits were scheduled at 1 month (T1) and 3 months (T2) post-injection.

The study was carried out in accordance with the International Conference of Harmonization, Good Clinical Practice guidelines, and the Declaration of Helsinki. Regarding regulatory aspects, MaiLi possesses the CE mark (BSI CE 2797) conforming with European health, safety and environmental protection standards. MaiLi is not commercialised in the U.S. and, as such, does not require FDA approval at this stage.

All subjects were provided with oral and written explanations. A signed informed consent form with details of the patient's expectations, the treatment plan, as well as possible contra-indications and complications, was obtained from all patients prior to patient preparation for the procedures, including an authorization to employ their images for scientific purposes.

The target population for inclusion was of 20 patients, five patients per site, over 18 years of age, who were willing to undergo esthetic procedures by means of dermal HA fillers. MaiLi® Precise is indicated for injections aiming at correcting wrinkles and fine lines or medium-sized skin depressions. Subjects presenting any contra-indication as per the instructions for using the MaiLi® device, such as known risk of hypersensitivity, pregnancy, or breastfeeding, were excluded from participation.

MaiLi® HA fillers based on OxiFree™ Technology

MaiLi® HA fillers are available in four different variants:

- MaiLi® Precise, used in the current study, is a 15 mg/mL HA gel particularly suited for filling fine wrinkles and injected using a 30G needle. This gel, indicated to treat the perioral area, is also indicated to treat the periorbital area and tear trough. Of note, the use of MaiLi® Precise in the periorbital area is reserved to specialists specifically trained in the injection technique, with sound knowledge of the anatomy and physiology of this area.
- MaiLi® Define, MaiLi® Volume, and MaiLi® Extreme, having a concentration of 18 mg/mL, 21 mg/mL, and 24 mg/mL respectively, are other MaiLi® fillers, which are less suited for treating very fine wrinkles.
- All MaiLi® products, including MaiLi® Precise, contain lidocaine 3%.

The Intradermal Injection Technique

For this procedure, preference is being given to products that are less reticulated, containing more fluid HA, which is the case for MaiLi® Precise. MaiLi® Precise was injected at an angle of penetration <10-12° into barcode lines using intradermal injections. In this procedure, the depth in which the gel amount (1 mL maximum) is injected with a 30G needle is very superficial in the dermal plane (intradermal). If necessary, topical or local anesthesia can be applied before injection to reduce pain. The patient could be either lying down or sitting up, given that the position is not essential for this technique. Physicians massaged the area with firm pressure in order to keep the filler in place and deliver a more homogenous result, as advised by the Sinclair guidelines. The injected area was cleaned after treatment, and the patients were advised to avoid hot drinks during one hour, refrain from smoking during 3 hours, and use sun protection during 1 week after the injection.

Assessments: Study Endpoints and Variables

The study endpoints and variables included treatment effectiveness based on the Global Aesthetic Improvement Scale (GAIS), patient satisfaction, investigator's satisfaction, in addition to Adverse Event (AE) rates and before/after photographs.

Global Aesthetic Improvement Scale: Treatment effectiveness was assessed based on the GAIS, a 5-point scale designed to grade post-injection appearance from "very much improved" to "much worse". The degree of improvement with reference to pre-injection levels was assessed for each patient at one (T1) and three months (T2) post-injection.

Patient and Physician Satisfaction: Patients were invited to rate their satisfaction level using a 5-point scoring system on different satisfaction items included in the questionnaire about treatment outcomes, ranging from "totally agree" to "totally disagree" at one (T1) and three (T2) months post-injection. The physician's satisfaction with the product and ease of injection were similarly recorded at the same time points using a similar 5-point scoring system.

Photograph: Front, three-quarter, and side profile photographs were taken at T0, T1, and T2.

Statistical Analysis: Descriptive statistical analyses were performed using Excel sheets for the GAIS, satisfaction scales, and AE data at baseline (T0), 1 month (T1), and 3 months (T2) post-injection. Adverse events were reported immediately after injection (T0), 1 month (T1), and 3 months (T2) after injection. The onset, duration, and severity of the AEs were also reported.

Results

Overall, 20 patients seeking treatments for barcode lines were included by four physicians, authors of the article, in four investigational sites between December 2022 and January 2023.

Characteristics of the population

All subjects were women, and their average age was 56 years old (full range being 39-71 years old). The age distribution is presented in Figure 1. The majority of the patients were between 50 and 59 years old (n=12/20, 60%)

Patient satisfaction

At T1 (Figure 2A), 95% of patients agreed that they were more satisfied with their appearance after MaiLi® treatment. Moreover, 90% of patients indicated that they felt better after the treatment, and that

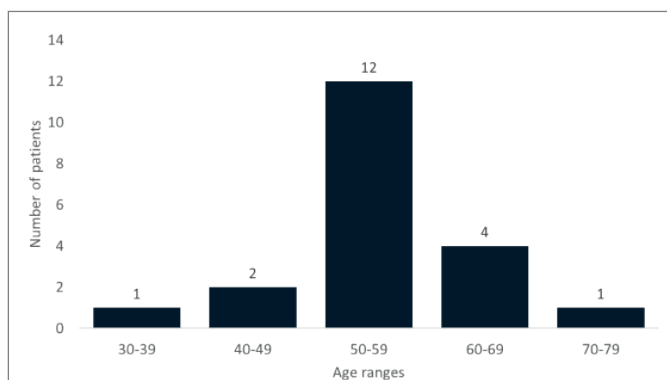


Figure 1: Age distribution of the patients injected with MaiLi® Precise (n=20).

they were satisfied with the smoothness of their skin. The remaining patients somewhat agreed. All patients agreed that they were more satisfied with the appearance of their wrinkles and of the area treated after MaiLi® treatment.

At T2 (Figure 2B), 90% of patients agreed that they were more satisfied with their appearance, the smoothness of their skin, and the appearance of the area treated after MaiLi® injection. Most patients (95%) were more satisfied with the appearance of their wrinkles after the treatment, and 90% of patients agreed that they felt better after MaiLi® injection. The remaining patients somewhat agreed.

Physician satisfaction

All physicians attributed improved, much improved, or very much improved GAIS scores - important and recognized criteria of efficacy evaluation, even if subjective - at both T1 (Figure 3A) and T2 (Figure 3B).

At T1 (Figure 4A), all physicians agreed that MaiLi® displayed better rheology than competitor products, and that the product was easy to inject. Moreover, all of them agreed that they would recommend MaiLi® to a colleague, taking into account that MaiLi® was easy to inject. Physicians were satisfied with the results of MaiLi® when using the intradermal injections, and they agreed that that the product was safe and effective. A large proportion of physicians involved in the study agreed that MaiLi® provided better results compared with competitor products generally used in their clinical practice, while the remaining 26% somewhat agreed.

At T2 (Figure 4B), the percentage of physicians agreeing to the different items were the same as at T1.

Photographs before and after MaiLi® Precise injection

The photographs of three patients are presented in Figure 5 before

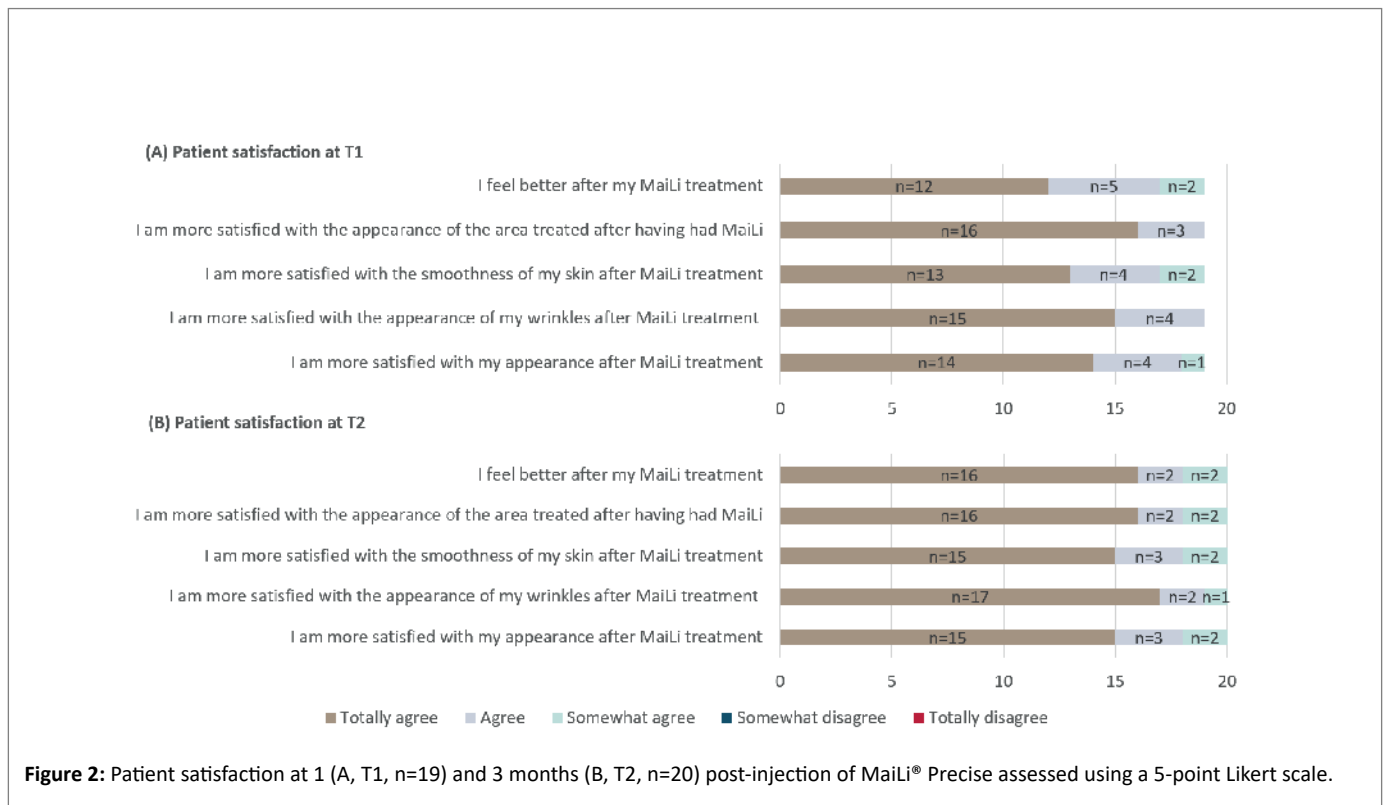

Figure 2: Patient satisfaction at 1 (A, T1, n=19) and 3 months (B, T2, n=20) post-injection of MaiLi® Precise assessed using a 5-point Likert scale.

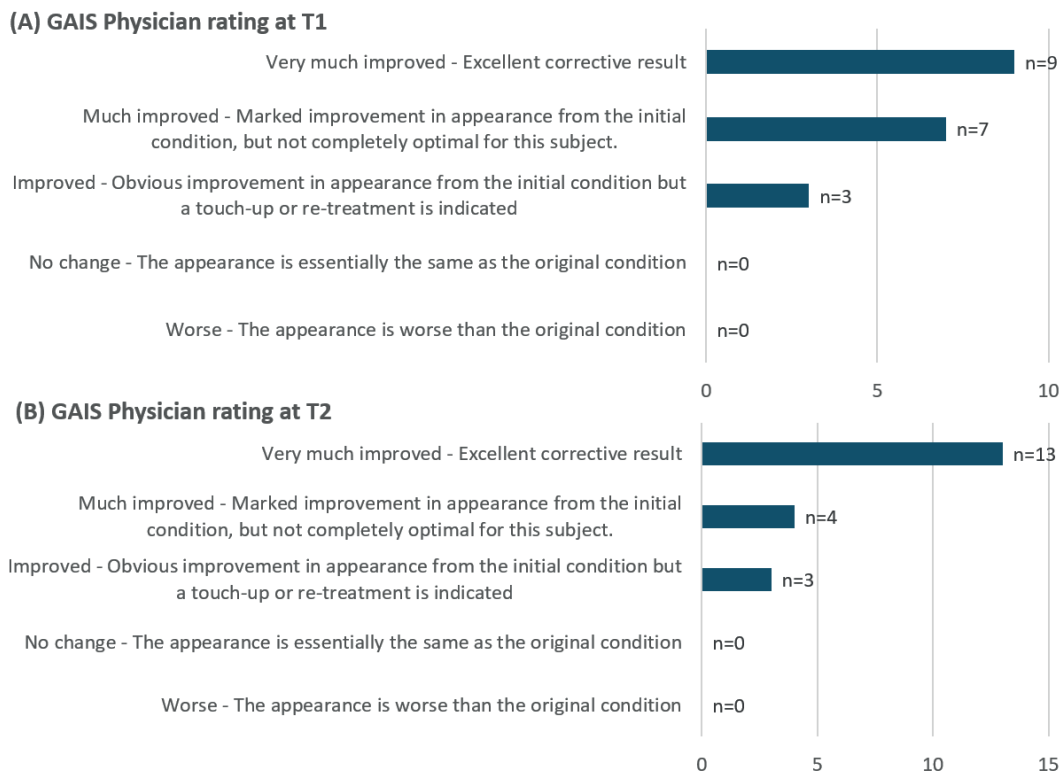


Figure 3: Global Aesthetic Improvement Scale (GAIS) scores attributed by the physicians for each patient at 1 (A, T1, n=19) and 3 months (B, T2, n=20) post-injection assessed using a 5-point Likert scale.

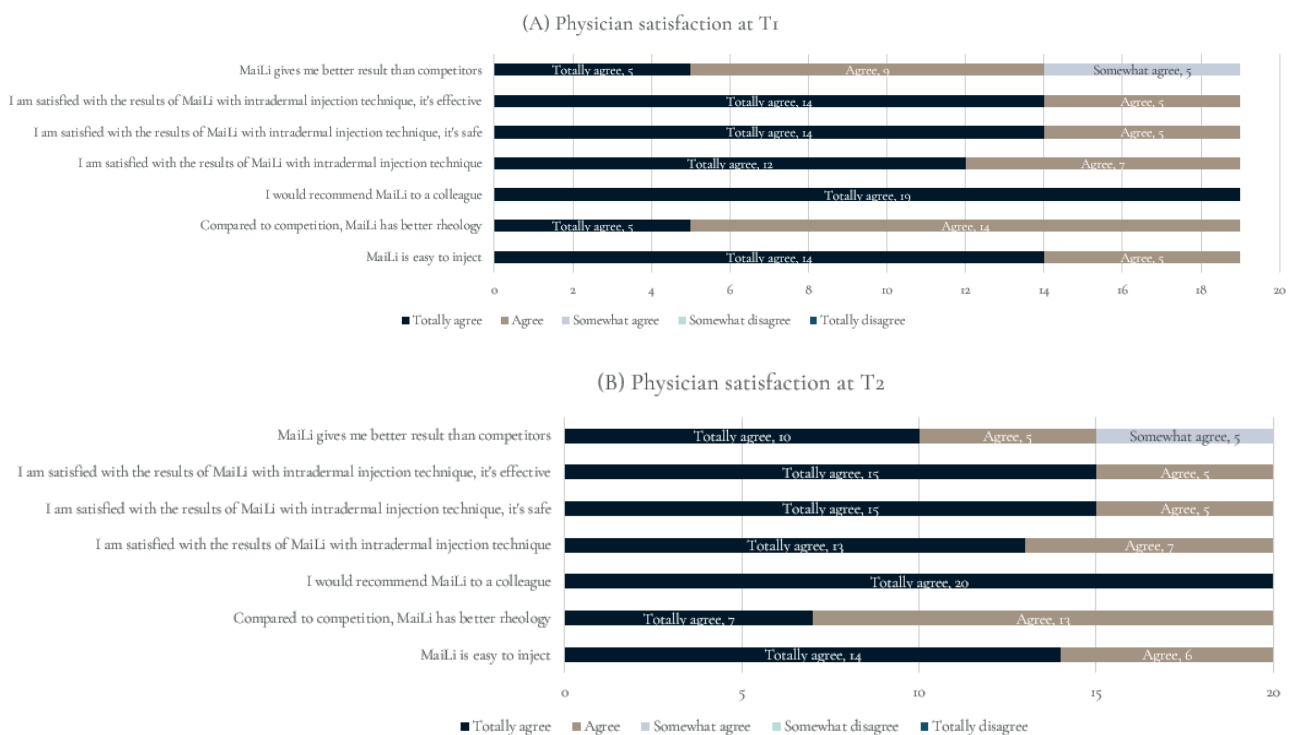


Figure 4: Physician satisfaction for each patient at 1 (A, T1) and 3 months (B, T2) post-injection assessed using a 5-point Likert scale.

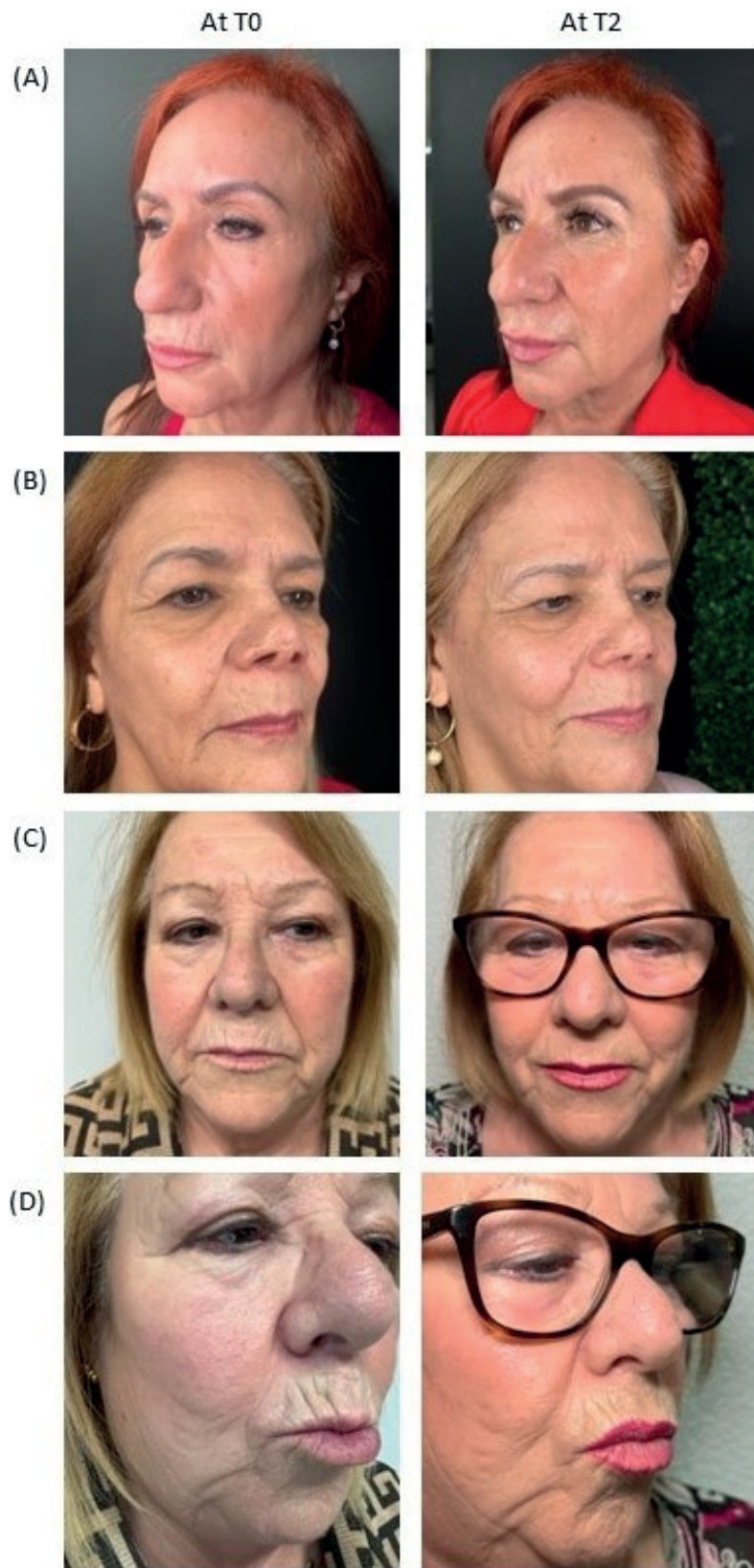

Figure 5: Photographs of three patients before injection (T0) and 3 months post-injection (T2).

(A) The patient was 57 years old and injected with 1mL of MaiLi® Precise. (B) The patient was 71 years old and injected with 1mL of MaiLi® Precise. (C & D) The patient was 69 years old and injected with 0.7mL of MaiLi® Precise.

injection with MaiLi® Precise (T0) and 3 months post-injection (T2), showcasing the desirable outcomes achieved. Patient ages and injected volumes are detailed in the caption. Figure 5C and 5D are pictures of the same patient, as we sought to showcase the effective result in both static and dynamic expressions - hence the two different angles and poses used for the same patient.

Safety

Of the reported AEs at T0 immediately after injection (70% of patients), the most common was redness, followed by swelling, discomfort, and itching, all reported as non-serious (Figure 6). At T1, the AE rate was only 15%, and the most commonly reported AEs were redness and hematoma. Overall, no product defects were found responsible for AE occurrence, with no unexpected AEs reported. All AEs were reported as non-serious and resolved/recovered. AEs were completely absent by T2 (3 months post-injection).

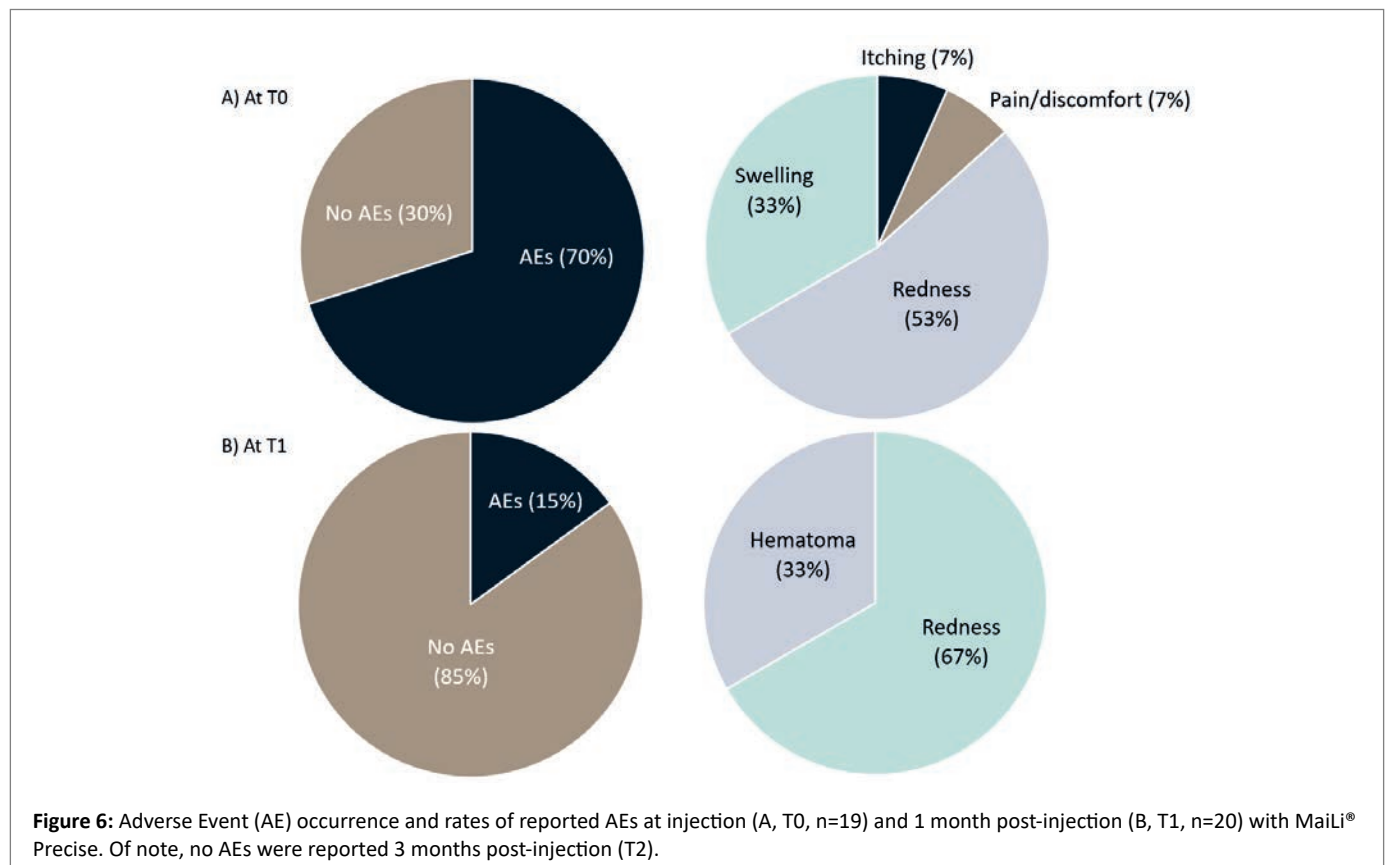
Discussion

Before commenting on the results of our study, we must remember that all HA gels are unique composition-wise, which conditions their properties. MaiLi® Precise is a product developed by using the OxiFree™ technology, its main advantages being to maintain the intrinsic properties of the high-molecular weight HA chains and to allow using smaller HA gel quantities [14]. Overall, this study demonstrated that the esthetic results after MaiLi® Precise injections were rated satisfactory or very satisfactory by >90% of patients and physicians. Mild AEs reported at T0 and T1 disappeared prior to T2, without any AEs reported at this follow-up point. Thus, in this pilot study, MaiLi® Precise has proven both efficient and safe in treating fine-line wrinkles with intradermal injections.

The long-lasting effects of HA fillers are still a matter of debate, but several studies have highlighted that these HA gels persist for a longer duration than expected [17,18]. Indeed, HA gels were thought to be reabsorbed within a few months, but several studies suggested that they persist for up to 18 to 24 months [19]. Our study did not include an assessment of persistence. However, the follow-up data extended to three months post-injection in our study, and both patients and physicians were satisfied about the esthetic result at that time point. Their rheological properties most probably exert a major influence on the duration of the MaiLi® HA filler effects, thus allowing for both a long-lasting effect and a certain ease during injections. Long-term Magnetic Resonance Imaging (MRI) follow-ups are currently being carried out and the awaited results should likely suggest that MaiLi® HA gels may provide advantages on the long-term effects compared to competitor products [14].

From the physician's point of view, MaiLi® gels are easy to inject, and the training for the injections usually involves only a short learning curve. All physicians either agreed or totally agreed that MaiLi® was effective, safe, easy to inject, and that they would recommend it to a colleague. Moreover, 75% of participating physicians agreed or totally agreed that MaiLi® provided better results than competitor products they generally used in their practice. Thus, given our results as well as those from previous research, physicians and patients should have confidence in MaiLi® products. Of note, the quality and safety of these recorded data are obviously ensured by the thorough application of the manufacturer's instructions.

More than 90% of patients were satisfied with their appearance after MaiLi® treatment; these data are perfectly in line with previous data involving a 1-year follow-up [14]. The last study's authors concluded



that MaiLi® HA fillers were at least as safe as the other cross-linked HA gels [14].

Considering the recorded AEs, there is a possibility of AE occurrence as inherent to all procedures of this type, although not everybody is likely to experience them. These AEs include, but are not limited to, injection-related events, contour irregularities, oedema, bruising, infection, vascular complications and longer-term events, including hypersensitivity to the ingredients, nodules, abscesses, granulomas and gel displacement. Of note, AEs due to product misplacement, overcorrection, or the injection procedure itself are far more common than AEs that are purely HA gel-related [20].

The good safety profile shown in the present study with MaiLi® Precise confirms the safety from post market surveillance data worldwide of the MaiLi® range of HA fillers, with a low overall incidence of AEs of 0.027% between February 2021 and April 2023. (Sinclair, Data on file).

Despite some limitations regarding the low number of patients and the lack of long-term evaluation, this study focusing on the effect on the perioral area further supports the efficacy and the good safety profile of MaiLi® Precise. This study was a pilot study, whose main aim was to assess the efficacy and safety of MaiLi® Precise in a limited number of subjects, as a first step. Future studies will certainly be carried out on a higher number of patients, with longer follow-up periods, to confirm our results. Moreover, these studies would benefit from the participation of a blinded evaluator for instance, as well as the use of a rating scale specific to the area of interest.

Conclusion

Using HA fillers has become increasingly popular for correcting perioral fine-line wrinkles. Treatment of the perioral area is deemed particularly challenging, yet the development of subtle, resilient HA fillers with optimal rheological properties delivering flexibility, outstanding projection capacity, and suppleness has rendered it possible to generate tissue restoration and rejuvenation effects, while enabling “natural-looking” results. This study demonstrated that MaiLi® Precise injections provided esthetic results judged very satisfactory by patients and physicians alike. Moreover, MaiLi® Precise is safe to use because the few AEs that occurred post-injection all remained very mild in nature, having completely disappeared at the last follow-up. Therefore, both physicians and patients should have full confidence in MaiLi® gels.

Acknowledgements

The authors wish to express their warmest appreciation to the 20 subjects for kindly agreeing to participate in the study.

Funding

This study was funded by Sinclair.

Conflicts of Interest

PBorregón is KOL for Sinclair; J Caicedo is KOL for Sinclair, BioScience GmbH, Apyx Medical; E Santaella is KOL for Sinclair; F Vercesi is KOL for Sinclair. P Borregón, J Caicedo, E Santaella, and F Vercesi were involved in the treatment of the patients, and all authors contributed to data analysis, revising the article, provided final approval of the version to be published, and agreed to be accountable for all aspects of the work. R Glacet, scientific director at Cremer Consulting, has no conflict of interest regarding the editorial content of the manuscript.

References

- Morera Serna E, Serna Benbassat M, Terré Falcón R, Murillo Martín J (2021) Anatomy and Aging of the Perioral Region. *Facial Plast Surg* 37: 176-193.
- Weinkle S (2010) Injection techniques for revolumization of the perioral region with hyaluronic acid. *J Drugs Dermatol* 9: 367-371.
- Grewal SK, Ortiz A (2022) Perioral Rejuvenation in Aesthetics: Review and Debate. *Clin Dermatol* 40: 265-273.
- Olenius M (1998) The first clinical study using a new biodegradable implant for the treatment of lips, wrinkles and folds. *Aesth Plast Surg* 22: 97-101.
- Duranti F, Salti G, Bovani B, Calandra M, Rosati ML (1998) Injectable hyaluronic acid gel for soft tissue augmentation. A clinical and histological study. *Dermatol Surg* 24: 1317-1325.
- Wollina U (2013) Perioral rejuvenation: restoration of attractiveness in aging females by minimally invasive procedures. *Clin Interv Aging* 8: 1149-1155.
- Gold MH (2007) Use of hyaluronic acid fillers for the treatment of the aging face. *Clin Interv Aging* 2: 369-376.
- Flynn TC, Sarazin D, Bezzola A, Terrani C, Micheels P (2011) Comparative histology of intradermal implantation of mono and biphasic hyaluronic acid fillers. *Dermatol Surg* 37: 637-643.
- Kim JH, Kang DW, Choi GW, Lee SB, Lee S, et al. (2021) Evaluation of Lidocaine and Metabolite Pharmacokinetics in Hyaluronic Acid Injection. *Pharmaceutics* 13: 203.
- Kim HJ, Kwon SB, Whang KU, Lee JS, Park YL, et al. (2018) The duration of hyaluronidase and optimal timing of hyaluronic acid (HA) filler reinjection after hyaluronidase injection. *J Cosmet Laser Ther* 20: 52-57.
- Gavard Molliard S, Albert S, Mondon K (2016) Key importance of compression properties in the biophysical characteristics of hyaluronic acid soft-tissue fillers. *J Mech Behav Biomed Mater* 61: 290-298.
- Gavard Molliard S, Bon Betemps J, Hadjab B, Topchian D, Micheels P, et al. (2018) Key rheological properties of hyaluronic acid fillers: from tissue integration to product degradation. *Plast Aesthet Res* 5: 17-24.
- Bon Betemps J, Marchetti F, Lim T, Hadjab B, Micheels P, et al. (2018) Projection capacity assessment of hyaluronic acid fillers. *Plast Aesthet Res* 5: 19.
- Micheels P, Poiraud M (2023) A Preliminary Report on the Safety and Efficacy of a Novel MaiLi HA Filler for Facial Correction of Wrinkles, Folds, Volume and Lips. *J Clin Cosmet Dermatol* 7.
- Micheels P, Sarazin D, Besse S, Sundaram H, Flynn TC (2013) A blanching technique for intradermal injection of the hyaluronic acid Belotero®. *Plast Reconstr Surg* 132: 595-685.
- Micheels P, Besse S, Flynn TC, Sarazin D, Elbaz Y (2012) Superficial dermal injection of hyaluronic acid soft tissue fillers: comparative ultrasound study. *Dermatol Surg* 38: 1162-1169.
- National Congress of the Spanish Society of Aesthetic Medicine (2020) Malaga, Spain.
- Sundaram H, Fagien S (2015) Cohesive polydensified matrix hyaluronic acid for fine lines. *Plast Reconstr Surg* 136: 149S-163S.
- Vandeputte J, Leemans G, Dhaene K, Forsyth R, Vanslembrouck J, et al. (2021) Spreading Pattern and Tissue Response to Hyaluronic Acid Gel Injections in the Subcutis: Ultrasound Videos, Ultrasound Measurements, and Histology. *Aesthet Surg J* 41: 224-241.
- Kroumpouzou G, Harris S, Bhargava S, Wortsman X (2023) Complications of fillers in the lips and perioral area: Prevention, assessment, and management focusing on ultrasound guidance. *J Plast Reconstr Aesthet Surg*. 2023 84:656-669.